



The effect of silymarin on liver injury induced by Thioacetamide in rats

Najmeh Kabiri¹, Mahboobeh Ahangar-Darabi², Mahbubeh Setorki³, Mahmoud Rafeian-kopaei^{4*}

¹MSc, Shahrekord University of Medical Sciences, Shahrekord, Iran

²Department of Biology, Faculty of Sciences, Isfahan University, Isfahan, Iran

³Department of Biology, Izeh Branch, Islamic Azad University, Izeh, Iran

⁴Medical Plants Research Center, Shahrekord University of Medical Sciences, Shahrekord, Iran

ARTICLE INFO

Article Type:
Original Article

Article History:
Received: 4 August 2013
Accepted: 6 November 2013
ePublished: 1 December 2013

Keywords:
Hepatoprotection
Thioacetamide
Silymarin
Rat

ABSTRACT

Introduction: In this study the protective effects of Silymarin was investigated against thioacetamide (TAA) induced hepatotoxicity in rat.

Methods: In an experimental study 24 male Wistar rats were designated in four equal groups as follows: Control group, the group treated with thioacetamide (TAA), Silymarin (400 mg/kg for 3 weeks) + TAA (400 mg/kg), TAA (400 mg/kg) + Silymarin (400 mg/kg for 3 weeks). The levels of serum aspartate transaminase (AST), alanine transaminase (ALT), alkaline phosphatase (ALP) lactate dehydrogenase (LDH) and total bilirubin were measured to assess the hepatotoxicity and hepatoprotection.

Results: TAA significantly increased AST, ALT, ALP, LDH and bilirubin. Treatment by Silymarin caused a significant reduction in serum levels of AST, ALT, ALP, LDH and bilirubin contents.

Conclusion: The results indicate a protective effect for Silymarin against thioacetamide induced hepatotoxicity which might be due to its ability to block the bioactivity of thioacetamide.

Implication for health policy/practice/research/medical education:

Silymarin has hepatoprotective activity against thioacetamide induced hepatotoxicity and its usage might be useful in patient who need to protect their body against hepatotoxic agents.

Please cite this paper as: Kabiri N, Ahangar-Darabi M, Setorki M, Rafeian-kopaei M. The effect of silymarin on liver injury induced by Thioacetamide in rats. J HerbMed Pharmacol. 2013; 2(2): 29-33.

Introduction

Liver cancer is one of common malignancies in the world, especially in Asia and Africa (1). Liver cirrhosis is induced by chronic liver injury, i.e. by viral hepatitis, alcoholic hepatitis, and parasitic diseases. This cirrhosis in turn, causes an imbalance in the proliferation of hepatocytes (2). Thioacetamide (TAA) is a classic hepatotoxic reagent used for the induction of liver cirrhosis (3). Ledda-Columbano et al. (1991) reported that thioacetamide induced apoptosis in the rat liver based on histochemical observations (4). In addition, it has been suggested that thioacetamide can also stimulate the DNA synthesis and mitosis in liver for hepatic regeneration (5). Indeed, the results of several studies have demonstrated beneficial effect of antioxidants in protecting the liver against TAA-induced injury (6,7). Antioxidants are expected to protect the liver from oxidative stress (8). The plant is known to possess antitumor (9,10), free radical scavenging and lipid peroxidation (11) activities. Numerous studies with have

been carried out to evaluate Silymarin/Silibinin on patients with adverse liver conditions (12). *Silybum marianum* L. is a member of the family (*Asteraceae*) widely used in traditional European medicine (12).

Silymarin, a polyphenolic flavonoid isolated from milk thistle, primarily consists of four isomeric compounds of active flavonolignans: silychristin, silydianin, and two groups of diastereoisomeric flavonolignans, silibinin, and isosilibinin (13). Silibinin, a flavanone, is the major and the most active component present in Silymarin that represents about 60–70% (14). Silymarin has clinical applications in the toxic hepatitis treatment, fatty liver, cirrhosis, ischaemic injury, radiation toxicity and viral hepatitis as a result of its antioxidative, anti-lipid-peroxidative, antifibrotic, anti-inflammatory, immunomodulating and even liver regenerating effects (15). In experiments on animals, Silymarin and Silibinin are shown to protect rat or mouse liver against hepatotoxicity induced by acute thioacetamide (16). It could also be useful in preventing

*Corresponding author: Mahmoud Rafeian-kopaei, Medical Plants Research Center, Shahrekord University of Medical Sciences, Shahrekord, Iran.
E-mail: rafeian@yahoo.com

a wide range of carcinogen and tumor promoter-induced cancers (17), Silymarin is a popular herbal product marketed to treat liver disorders (18).

This study was designed to evaluate the hepatoprotective and antioxidant potentials of Silymarin against thioacetamide induced liver injury in rats.

Materials and Methods

Animals and Treatment

Twenty four male Wistar rats (200-250 g of body weight) were prepared from animal house of Isfahan University of Medical Sciences and were kept under controlled temperature (23 ± 2 °C) and 12:12 h light-dark cycle conditions. The animals were divided into four groups.

Group 1: control.

Group 2: injected with TAA (400 mg/kg) for 2 weeks.

Group 3: injected with TAA (400 mg/kg) and then Silymarin (400 mg/kg) for 3 weeks.

Group 4: injected with Silymarin (400 mg/kg b.w) for 3 weeks and then with TAA (400 mg/kg).

At the end of the experiment the rats were sacrificed by anesthetic overdose and samples of serum and liver were collected.

Biochemical evaluation

Serum samples obtained from the rats were analyzed for alanin aminotransferase (ALT), aspartate aminotransferase (AST), alkaline phosphatase (ALP), lactate dehydrogenase (LDH), total cholesterol (Chol), LDL-cholesterol (LDL-C), HDL-cholesterol (HDL-C) and triglyceride (TG). Blood samples were collected from inferior cava vein after anesthesia and measured using special kits (DiaSys, Germany) which utilized the colorimetric method, in an autoanalyzer (Hitachi autoanalyzer, Hitachi Co., Tokyo). Bilirubin was also measured.

Histopathological analysis

The tissues were fixed in 10% buffered formalin, embedded in paraffin, sectioned and stained with hematoxylin and eosin (H&E) for histological studies.

Statistical analysis

The data obtained was subjected to one way ANOVA and Tukey's multiple comparison test using SPSS statistical package (Version 13.0). Values were expressed as mean \pm SD. P value $p < 0.05$ was considered significant.

Results

The daily access to food and water was controlled in the period and no difference in body weight gain was observed among all groups at the end (Table 1).

The levels of liver enzymes, bilirubin and lipids factors in serum of control group had no significant difference in the beginning of the study. Rats treated with Thioacetamide (TAA) developed significant hepatic damage as indicated from elevated serum levels of hepatospecific enzymes AST, ALT, ALP and LDH (Table 1). Serum bilirubin level was enhanced by TAA treatment. Serum total cholesterol (Chol), HDL-cholesterol (HDL-C) and triglyceride (TG) levels were considerably reduced and LDL-cholesterol (LDL-C) increased by TAA treatment (Table 1). The treatment by Silymarin produced a significant reduction in serum enzyme levels (AST, ALT, ALP, LDH) and reduction in bilirubin content (Table 1). The plasma AST, ALT, ALP and LDH were significantly decreased in Group 4 (Silymarin and then thioacetamide) compared to the thioacetamide group and were even comparable to the control group and a reduction in bilirubin content (Table 1). Histopathological evaluation indicates that compared to normal group (Figure 1), TAA caused focal necrosis, increase in mitosis at cells, apoptosis, abnormally mitosis, inflammation at portal space and large

Table 1. Effect of Thioacetamide and silymarin treatment on rat body weight, liver weight, and biochemical parameters

Parameters	Groups			
	control	TAA	TAA+Silymarin	Silymarin +TAA
ALT(U/L)	148 \pm 26.058	767 \pm 16.971*	89.60 \pm 17.658**	202.75 \pm 4.992**
AST(U/L)	184.33 \pm 62.324	653 \pm 53.033*	125.80 \pm 6.301**	296.25 \pm 61.402**
ALP(U/L)	614.67 \pm 196.398	1593.50 \pm 214.253*	623.6 \pm 160.982**	1199.60 \pm 172.216**
LDH(U/L)	1116.33 \pm 74.272	1269.50 \pm 6.364	862.60 \pm 298.458**	1799 \pm 130.186**
TG(mg/dl)	29.33 \pm 16.563	11 \pm 1.414	48.20 \pm 13.274**	12.75 \pm 2.217
cho(mg/dl)	88.67 \pm 13.051	64.50 \pm 3.536*	77.4 \pm 4.278**	81.20 \pm 12.518
LDL(mg/dl)	10 \pm 2.646	16 \pm 0.0	12.25 \pm 2.168**	20.60 \pm 2.608
HDL(mg/dl)	42.33 \pm 5.859	30 \pm 5.657	44.40 \pm 2.408**	37.80 \pm 8.672
Bilirubin(mg/dl)	0.4833 \pm 0.028	1.05 \pm 0.63	0.63 \pm 0.044	0.55 \pm 0.141
BW (g)	244.76 \pm 32.712	191.93 \pm 10.909	196.84 \pm 28.047	216.26 \pm 21.257
LW (g)	8.47 \pm 0.32	7.38 \pm 0.72	7.38 \pm 1.21	7.68 \pm 0.64
LW/BW (%)	3.46 \pm 0.2	3.84 \pm 0.1	3.74 \pm 0.3	3.55 \pm 0.1

Note. Body and liver weights were recorded at the time of killing. Abbreviation are Alanin aminotransferase (ALT), Aspartataminotransferase (AST), Alkaline phosphatase (ALP), Lactate dehydrogenase (LDH), total cholesterol (Chol), LDL-cholesterol (LDL-C), triglyceride (TG) and HDL-cholesterol (HDL-C), body weight (BW) and liver weight (LW). Data are expressed as the mean \pm SD.

* $P < 0.05$ vs. controls.

** $P < 0.05$ vs. TAA

nucleus (Figure 2). Necrosis, a more severe form of injury was markedly prevented by natural Silymarin especially by 400 mg/kg body weight (Figure 3). In the Silymarin treatment group, some cells had large nucleus but there were not apoptosis and mitosis (Figure 4) and in the Silymarin prevention group +TTA, and TTA+ Silymarin these changes were not observable.

Discussion

Thioacetamide (TAA) is widely used for experimentally induced liver injury. While acute TAA application results in hepatitis (19), chronic TAA application has been shown to cause liver cirrhosis (20). It has been reported that oxidative stress contributes significantly to the pathogenesis of TAA-induced hepatitis and cirrhosis (20). However, the mechanism of oxidative stress in TAA hepatotoxicity is still unclear. TAA S-oxide and TAA S-dioxide are the essential very reactive compounds produced during cytochrome-P450-mediated oxidation of TAA, in addition to the free radicals (21). Thioacetamide can be metabolized in more toxic metabolite and thioacetamide S-oxide, by P450 enzyme (22). In addition, well-known P450 inhibitor, SKF-525A, is protected against the hepatic necrosis caused by thioacetamide and thioacetamide S-oxide, suggesting that both thioacetamide and thioacetamide S-oxide are activated by hepatic mixed-function oxidase enzymes to a hepatotoxic compound (22). The P450 2B enzyme is implicated to selectively metabolize thioacetamide to its S-oxide metabolite (23). In this study, a sub-lethal dose of TAA (400 mg/kg) was used for 10 days, because TAA-induced liver injury has been reported to be evident at this time in experimental studies. Significant increases in AST, ALT, ALP, LDH plasma and increase in bilirubin level as well as histopathological liver necrosis findings were observed. In this study, increase in AST, ALT,

ALP, LDH and bilirubin levels induced by thioacetamide was significantly reduced by Silymarin. This hepatoprotective activity might be due to its effect against cellular leakage and loss of functional integrity of the cell membrane in liver. Silymarin is a popular herbal product marketed to treat liver disorders (18). The results from the studies indicate that Silymarin has good hepatoprotective and has antioxidant potential against diethylnitrosamine induced hepatocellular damage in rats (24-26).

In the recent years, increasing body of evidence has underscored the cancer preventive efficacy of Silymarin in both *in vitro* and *in vivo* animal models of various epithelial cancers (25). Silybin acts mainly as an effective radical scavenger (antilipoperoxidant) (26) and as an antioxidant, as well (27). Recently, the results of numerous experimental studies strongly suggest that Silybin (and/or Silymarin) hepatoprotective effects are mainly due to free radical scavenging (28). Silibinin as an effective anti-cancer and chemopreventive agent in various epithelial cancer models

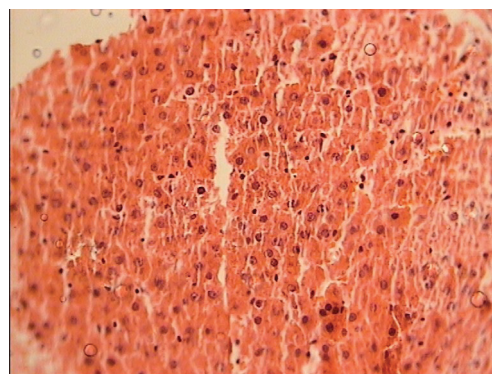


Figure 1. Liver histopathology of control group, 40X

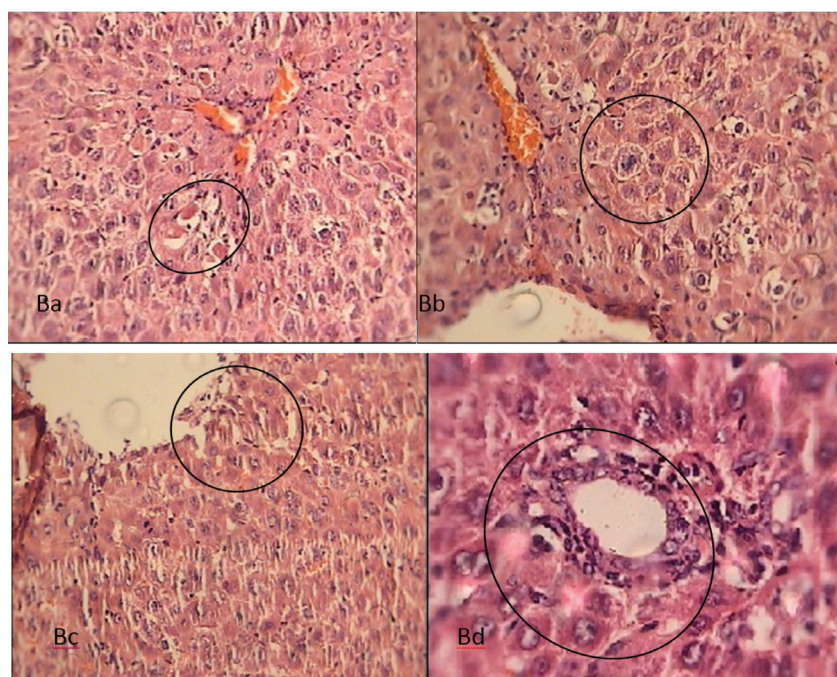


Figure 2. Liver histopathology of group 2 (B), Animals were injected (i.p.) TAA (400 mg/kg) for 2 weeks; Ba: Abnormal mitosis, Bb: Apoptosis, Bc: Mitosis Bd: Inflammation around the porta area; 40X

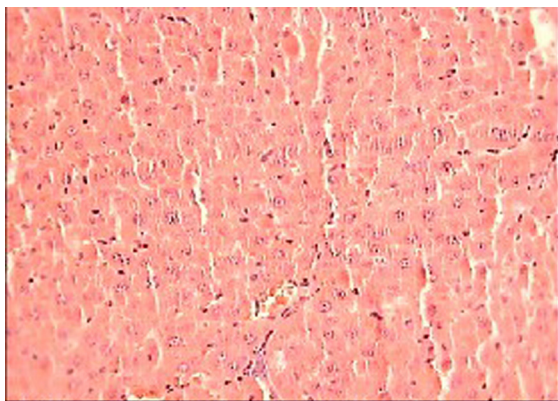


Figure 3. Liver histopathology of group 3 (C), Animals were injected TAA (400 mg/kg and then silymarin (400 mg/kg) for three weeks. 40X

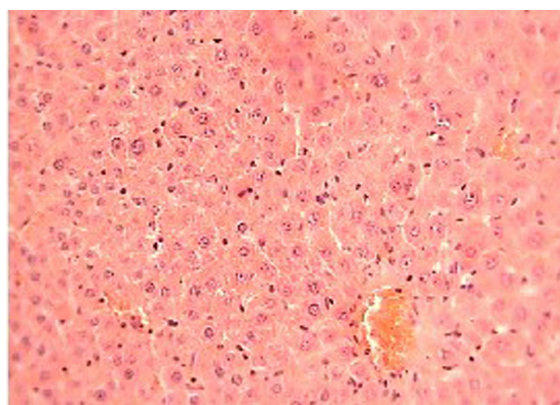


Figure 4. Liver histopathology of group 4 (D), Animals were injected silymarin (400 mg/kg) for three weeks and then TAA (400 mg/kg), 40X

is reported as an inhibitor of cancer cell growth through mitogenic signaling pathways. However, whether it can inhibit renal cell carcinoma growth and the underlying mechanisms is still not well elucidated (29). Muriel and Mourelle have shown that Silibinin preserves the functional and structural integrity of hepatocyte membranes by preventing alterations of their phospholipid structure produced by carbon tetrachloride and by restoring alkaline phosphatase and GGT activities (30). Which has anti-inflammatory, cytoprotective, and anticarcinogenic effects, that suppress the TNF-induced production of ROS and lipid peroxidation (31) and improve the antioxidant status in blood and liver (32). The mechanism action of hepatoprotection provided by Silymarin appears to rest on four properties:

Activity against lipid peroxidation as a result of free radical scavenging and the ability to increase the cellular content of GSH; ability to regulate membrane permeability and to increase membrane stability in the presence of xenobiotic damage; capacity to regulate nuclear expression by means of a steroid-like effect; inhibition of the transformation of stellate hepatocytes into myofibroblasts, responsible for the deposition of collagen fibers leading to cirrhosis.

Silymarin and Silibinin inhibit the absorption of toxins, such as phalloidin or α -amanitin, preventing them from binding to the cell surface and inhibiting membrane transport systems (27). The administration of Silymarin reduces plasma levels of cholesterol and low-density lipoprotein (LDL) cholesterol in hyperlipidaemic rats, whereas Silibinin does not reduce

plasma levels of cholesterol in normal rats; however, it does reduce phospholipid levels, especially those transported in LDL (33). Silymarin and quercetin are polyphenolic flavonoids that increase cell resistance to lipid peroxidation (34).

This study demonstrates that the hepatoprotective effect of silymarin against thioacetamide-induced hepatotoxicity might be a result of multiple mechanisms. It is thought that Silymarin has beneficial effect on liver, but more detailed biochemical and histopathological studies are necessary in order to confirm this effect in thioacetamide-induced toxicity.

Acknowledgements

The work was derived from an MSc thesis and was supported in Part by a grant number 81123 from Isfahan Cardiovascular Research Center (ICRC) and partly by Isfahan University. We would like to thank Isfahan Cardiovascular Research Center and their esteemed Basic Science Laboratory staffs.

Authors' contributions

All authors participated in the study, have read the manuscript, and provided their final approval.

Conflict of interests

The authors declared no competing interests.

Ethical considerations

Ethical issues (including plagiarism, misconduct, data fabrication, falsification, double publication or submission, redundancy) have been completely observed by the authors.

Funding/Support

None.

References

1. Lemoine A, Azoulay D, Jezequel M, Debuire B. Hepatocellular carcinoma. *Pathol Biol* 1999;47: 903-910.
2. Malizia G, Brunt EM, Peters MG, Rizzo A, Broekelmann TJ, McDonald JA. Growth factor and procollagen type I gene expression in human liver disease. *Gastroenterology* 1995; 108:145-56.
3. Nozu F, Takeyama N, Tanaka T. Changes of hepatic fatty acid metabolism produced by chronic thioacetamide administration in rats. *Hepatology* 1992;15:1099-106.
4. Ledda-Columbano GM, Coni P, Curto M, Giacomini L, Faa G, Oliverio S, et al. Induction of two different modes of cell death, apoptosis and necrosis, in rat liver after a single dose of thioacetamide. *Am J Pathol* 1991;139: 1099-1109.
5. Mangipudy RS, Chanda S, Mehendale HM. Tissue repair response as a function of dose in thioacetamide hepatotoxicity. *Environ Health Perspect* 1995;103: 260-267.
6. Balkan J, Dogru-Abbasog S, Kanbag O, Cevikbas U, Aykac-Toker G, Uysal M. Taurine has a protective effect against thioacetamide-induced liver cirrhosis by decreasing oxidative stress. *Hum Exp Toxicol* 2001; 20:251-64.
7. Sehrawat A, Khan TH, Prasad L, Sultana S. Butea monosperma and chemomodulation: protective role against thioacetamide-mediated hepatic alterations in Wistar rats. *Phytomedicine* 2006;13:157-63.

8. Kazemi S, Asgary S, Moshtaghian J, Rafeian M, Adelnia A, Shamsi F. Liver-protective effects of hydroalcoholic extract of *allium hirtifolium* boiss. In rats with alloxan-induced diabetes mellitus. *ARYA Atheroscler* 2010;6(1):11-5.
9. Shirzad H, Shahrani M, Rafeian-Kopaei M. Comparison of morphine and tramadol effects on phagocytic activity of mice peritoneal phagocytes in vivo. *Int Immunopharmacol* 2009;9(7-8):968-70.
10. Shirzad H, Taji F, Rafeian-Kopaei M. Correlation between antioxidant activity of garlic extracts and WEHI-164 fibrosarcoma tumor growth in BALB/c mice. *J Med Food* 2011;14(9):969-74.
11. Rafeian-Kopaei M, Baradaran A. Plants antioxidants: From laboratory to clinic. *J Nephropathol* 2013;2(2): 152-153.
12. Heidarian E, Rafeian-Kopaei M. Effect of silymarin on liver phosphatidate phosphohydrolase in hyperlipidemic rats. *Biosci Res* 2012;9(2):59-67.
13. Wu JW, Lin LC, Hung SC, Chi CW, Tsai TH. Analysis of silibinin in rat plasma and bile for hepatobiliary excretion and oral bioavailability application. *J Pharm Biomed Anal* 2007;45: 635-641.
14. Saller R, Meier R, Brignoli R. The use of silymarin in the treatment of liver diseases . *Drugs* 2001;61: 2035-2063.
15. Luper S. A review of plants used in the treatment of liver disease: part I. *Altern Med Rev* 1998; 3: 410-21
16. Schriewer H, Lohmann J. [Disturbances in the regulation of phospholipid metabolism of the whole liver, mitochondria and microsomes in acute thioacetamide poisoning and the influence of silymarin]. *Arzneimittelforschung* 1976;26:65-69.
17. Zhao J, Lahiri-Chatterjee M, Sharma Y, Agarwal R. Inhibitory effect of a flavonoid antioxidant silymarin on benzoyl peroxide-induced tumor promotion, oxidative stress and inflammatory responses in SENCAR mouse skin. *Carcinogenesis* 2000;21: 811-816.
18. Wu JW, Lin LC, Chi CW, Tsai TH. Drug-drug interactions of silymarin on the perspective of pharmacokinetics. *J Ethnopharmacol* 2009; 121:185-193.
19. Bruck R, Aeed H, Shirin H, Matas Z, Zaidel L, Avni Y, et al. The hydroxyl radical scavengers dimethylsulfoxide and dimethylthiourea protect rats against thioacetamide-induced fulminant hepatic failure. *J Hepatol* 1999; 31: 27-38.
20. Natarajan SK, Thomas S, Ramamoorthy S, Basivireddy J, Pulimood AB, Ramachandran A, et al. Oxidative stress in the development of liver cirrhosis: a comparison of two different experimental models. *J Gastroenterol Hepatol* 2006; 21:947-57.
21. Chieli E, Malvaldi G. Role of themicrosomal FAD-containing monooxygenase in the liver toxicity of thioacetamide S-oxide. *Toxicology* 1984;31:41-52.
22. Hunter AL, Holscher MA, Neal RA. Thioacetamide-induced hepatic necrosis. I. Involvement of the mixed-function oxidase enzyme system. *J Pharmacol Exp Ther* 1977;200(2):439-48.
23. Porter WR, Neal RA. Metabolism of thioacetamide and thioacetamide S-oxide by rat liver microsomes. *Drug Metab Dispos* 1978;6:379-88.
24. Pradeep K, Mohan CVR, Gobianand K, Karthikeyan S. Silymarin modulates the oxidant-antioxidant imbalance during diethylnitrosamine induced oxidative stress in rats. *Eur J Pharmacol* 2007; 560: 110-116
25. Kaur M. Silymarin and epithelial cancer chemoprevention: How close we are to bedside? *Toxicol Appl Pharmacol* 2007; 224:350-359
26. Mira L, Silva M, Manso CF. Scavenging of reactive oxygen species by silibinin dihemisuccinate. *Biochem Pharmacol* 1994;48(4):753-759.
27. Valenzuela A, Garrido A. Biochemical bases of the pharmacological action of the flavonoid silymarin and of its structural isomer silibinin. *Biol Res.* 1994; 27: 105-12.
28. Gazak R, Walterova D, Kren V. Silybin and silymarin- new and emerging applications in medicine. *Curr Med Chem* 2007; 14:315-338
29. Li L, Gao Ye , Zhang L, Zeng J, He D, Sun Y. Silibinin inhibits cell growth and induces apoptosis by caspase activation, down-regulating survivin and blocking EGFR-ERK activation in renal cell carcinoma. *Cancer Lett* 2008; 272:61-69.
30. Muriel P, Mourelle M. Prevention by silymarin of membrane alterations in acute CCl₄ liver damage. *J Appl Toxicol* 1990;10:275-9.
31. Manna SK, Mukhopadhyay A, Van NT, Aggarwal BB. Silymarin suppresses TNF-induced activation of NF- κ B, c-Jun Nterminal kinase, and apoptosis. *J Immunol* 1999 163: 6800-6809.
32. Skottova N, Kazdova L, Oliarnyk O, Vecer AR, Sobolova L, Ulrichova J. Phenolics-rich extracts from *Silybum marianum* and *Prunella vulgaris* reduce a high-sucrose diet induced oxidative stress in hereditary hypertriglyceridemic rats. *Pharmacol Res* 2004; 50: 123-130.
33. Skottova N, Kreeman V. Silymarin as a potential hypocholesterolaemic drug. *Physiol Res* 1998;47:1-7.
34. Kravchenko LV, Morozov SV, Tutel'yan VA. Effects of flavonoids on the resistance of microsomes to lipid peroxidation in vitro and ex vivo. *Bull Exp Biol Med* 2003;136:572-575.